

# Intraoperative Embolic Events During Total Knee Arthroplasty with Use of Pulsatile Saline versus Carbon Dioxide Lavage

<sup>+</sup>Lassiter, T E; <sup>1</sup>Schroeder, R A; <sup>1</sup>McDonagh, D L; <sup>2</sup>Bolognesi, M P; <sup>3</sup>Sarin, V K; <sup>1</sup>Monk, T G  
<sup>+</sup>Department of Anesthesiology, Veterans Affairs Medical Center, Duke University Medical Center, Durham, NC  
<sup>2</sup>Division of Orthopaedic Surgery, Duke University Medical Center, Durham, NC  
<sup>3</sup>Kinamed Incorporated, Camarillo, CA

## INTRODUCTION

Elderly patients are at risk of developing cardiopulmonary and cognitive impairment following major orthopaedic surgery<sup>6,14</sup>. One of the mechanisms believed to be responsible for such complications after total knee arthroplasty (TKA) is the release of embolic debris that may travel from the surgical site, through the heart and lungs, and into the brain<sup>6,15,18</sup>, contributing to lower arterial oxygen tension, oxygen saturation, end-tidal carbon dioxide tension, arterial blood pressure, and heart rate<sup>6,10</sup>. Removal of fat globules and marrow particulates from bone surfaces prior to pressurization and cementation of prosthetic components has been shown to reduce the number and size of embolic particles<sup>4,19</sup>. We conducted a prospective, randomized clinical trial to compare the effect of carbon dioxide (CO<sub>2</sub>) gas lavage<sup>1,7,8,13</sup> versus saline lavage on the number and size of embolic particles observed during cemented TKA.

## METHODS

This prospective study was approved by the local institutional review board and informed consent was obtained for all enrollees.

Twenty patients undergoing elective TKA were randomly assigned to one of two groups. In group A, standard high-pressure pulsatile saline lavage was used to clean the resected bone surfaces. In group B, the femoral canal was cleaned using CO<sub>2</sub> lavage techniques and the resected bone surfaces were cleaned with a manual saline wash followed by CO<sub>2</sub> lavage. All patients received the same TKA implant design.

The presence of embolic particles in the heart and brain was intraoperatively monitored using transesophageal echocardiography (TEE) and transcranial Doppler (TCD) techniques, respectively. For each patient, TEE images were analyzed at tourniquet release and during the final range of motion (ROM) assessment prior to wound closure using the following five point cardiac echogenic scoring system<sup>3</sup>: Grade 0: no emboli; Grade I: a few fine emboli; Grade II: a cascade of many fine emboli; Grade III: a cascade of fine emboli mixed with at least one embolus > 1 cm in diameter; and Grade IV: large embolic masses > 3 cm in diameter. The highest grade observed during either tourniquet release or ROM assessment was assigned to each patient. Based on previous studies<sup>2,16</sup>, patients were categorized as having a Low (Grade 0 or I) or High (Grade II, III, or IV) cardiac embolic load.

For analysis of cerebral emboli, the total number of amplitude peaks (i.e. counts) measured using TCD was recorded for each patient. Patients were categorized as having Low (< 5) or High (≥ 5) cerebral counts.

TEE data were available for nine patients in group A and eight patients in group B. Comparative TCD data were available for seven patients in group A and six patients in group B.

Fischer's Exact Test was used to check for differences between groups.

## RESULTS

For cardiac emboli, nine of nine (100%) patients in group A were in the High category based on their TEE grade, with eight patients being Grade II and one Grade III (Figure 1). In contrast, only five of eight (62.5%) patients in group B were in the High category, leaving three (37.5%) in the Low category (p = 0.08) (Figure 1). All five group B patients in the High category were Grade II (none were Grade III).

For cerebral emboli, no patient in either group had a High cerebral count. Seven of seven patients in Group A were in the Low category (all seven had 0 counts), while six of six patients in Group B were in the Low category (three had 0 counts and three had 1 count). Three patients in group B were excluded from the comparative TCD analysis due to the presence of a patent foramen ovale (PFO). These three patients with a PFO were also in the Low category, having 1, 3, and 4 counts, respectively. No patients in group A had a PFO.

## DISCUSSION

This study examines the effect of pulsatile saline versus CO<sub>2</sub> gas lavage on intraoperative embolic events during TKA. Thirty-seven percent of patients in the CO<sub>2</sub> lavage group had a Low cardiac echogenic load compared with 0% of patients in the standard pulsatile saline lavage group. The incidence of cardiac emboli was low compared to previous studies<sup>2,5,10,11</sup> on conventional TKA. The incidence of cerebral emboli was Low for both groups and for patients who had a patent foramen ovale. Previous studies<sup>9,12,17,18</sup> on cerebral emboli in conventional TKA report up to 43, 34, 40, and 100 counts, respectively.

The results of this study suggest that CO<sub>2</sub> gas lavage, as compared to pulsatile saline lavage, reduces the number of intraoperative cardiac emboli during total knee arthroplasty. Additional studies with larger sample sizes are planned.

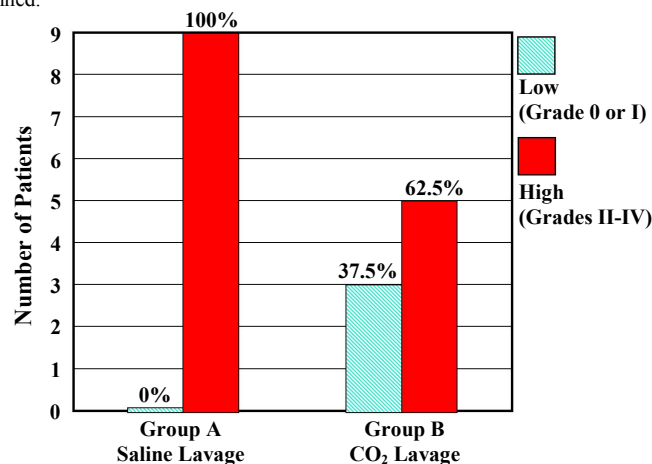


Figure 1. Cardiac embolic events during total knee arthroplasty with pulsatile saline lavage versus CO<sub>2</sub> lavage. Patients in the CO<sub>2</sub> lavage group had a 37.5% lower incidence of High cardiac embolic load compared to patients in the saline lavage group (p = 0.08).

## REFERENCES

- Amstutz et al (2006) Metal-on-metal hybrid surface arthroplasty. Surgical Technique. J Bone Jt Surg 88-A:234.
- Berman et al (1998) Emboli observed with use of transesophageal echocardiography immediately after tourniquet release during total knee arthroplasty. J Bone Jt Surg 80-A:389.
- Christie et al (1994) Echocardiography of transarticular embolism during cemented and uncemented hemiarthroplasty of the hip. J Bone Jt Surg 76-B:409.
- Christie et al (1995) Medullary lavage reduces embolic phenomena and cardiopulmonary changes during cemented hemiarthroplasty. J Bone Jt Surg 77-B:456.
- Church et al (2007) Embolic phenomena during computer-assisted and conventional total knee replacement. J Bone Jt Surg 89-B:481.
- Fahmy et al (1990) Blood gas and circulatory changes during total knee replacement: role of the intramedullary alignment rod. J Bone Jt Surg 72-A:19.
- Goldstein et al (2007) Improvement of cement mantle thickness with pressurized carbon dioxide lavage. 20<sup>th</sup> Annual Meeting of the International Society for Technology in Arthroplasty.
- Higgs et al (2008) A radiological comparison of cement mantle thickness around total knee arthroplasty with or without the use of pressurized carbon dioxide lavage. 68<sup>th</sup> Annual Meeting of the Australian Orthopaedic Association.
- Kalairajah et al (2006) Are systemic emboli reduced in computer-assisted knee surgery? J Bone Jt Surg 88-B:198.
- Kim (2001) Incidence of fat embolism syndrome after cemented or cementless bilateral simultaneous and unilateral total knee arthroplasty. J Arthroplasty 16:730.
- Kim et al (2008) Prevalence of fat embolism after total knee arthroplasty performed with or without computer navigation. J Bone Jt Surg 90-A:123.
- Lavernia et al (2006) Cognitive dysfunction in arthroplasty surgery: cerebral fat embolism? 52<sup>nd</sup> Annual Meeting of the Orthopaedic Research Society.
- McTigue et al (1995) The use of carbon dioxide gas for preparation of bony surfaces in cemented total joint arthroplasty. 8<sup>th</sup> Annual Meeting of the International Society for Technology in Arthroplasty.
- Monk et al (2008) Predictors of cognitive dysfunction after major noncardiac surgery. Anesthesiology 108:18.
- Morawa et al (1996) Transesophageal echocardiographic monitored events during total knee arthroplasty. Clinical Orthop Rel Research 331:192.
- Pitto et al (1999) Comparison of fixation of the femoral component without cement and fixation with use of a bone-vacuum cementing technique for the prevention of fat embolism during total hip arthroplasty. J Bone Jt Surg 81-A:831.
- Rodriguez et al (2005) Cognitive dysfunction after total knee arthroplasty. J Arthroplasty 20:763.
- Sulek et al (1999) Cerebral microembolism diagnosed by transcranial doppler during total knee arthroplasty. Anesthesiology 91:672.
- Wheelwright et al (1993) Hypotension during cemented arthroplasty. J Bone Jt Surg 75-B:715.