

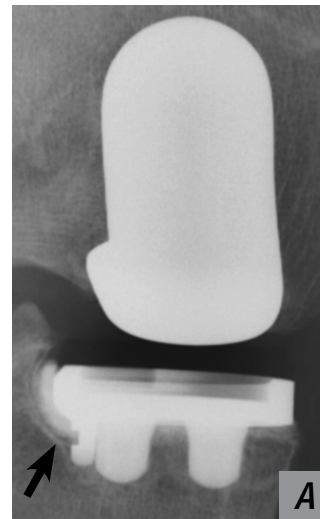
Bone Preparation in Cemented Partial Knee Replacement using Pressurized CO₂ Gas Jet System

Dennis McGee, MD, Saint Alphonsus Medical Group, Boise, Idaho

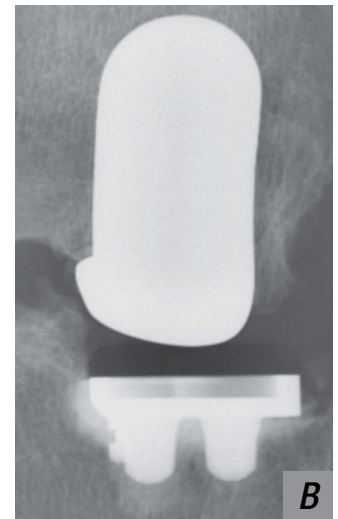Aseptic loosening is the most common cause for revision of unicompartmental knee arthroplasty (UKA)^{1,2}. This fact highlights the importance of achieving optimum cement fixation via meticulous and effective cleaning and drying of the bone bed. Improved cement penetration and interdigitation into the cancellous bone offers the potential for a reduction in aseptic loosening rates and increased longevity in UKA. Increased cement mantle thickness has also been shown to greatly decrease peak stresses transmitted to the cement interfaces in UKA³. Pressurized CO₂ bone preparation utilizing the CarboJet® system has demonstrated improved cement penetration, cement mantle thickness^{4,5} and bone-cement interface strength⁶ compared to saline lavage. In particular, the small diameter angled nozzle of the CarboJet system allows effective access for debris removal in tight spaces with less exposure, as during UKA. Excellent cement mantle thickness and consistency, with fewer radiolucent lines, has been observed with the use of CarboJet combined with simple bulb syringe saline lavage in my UKA cases.



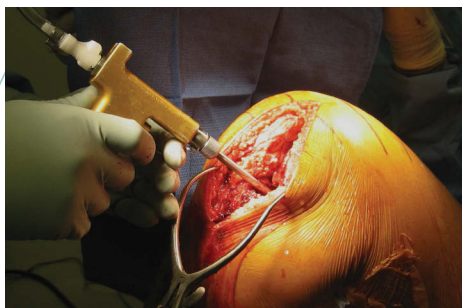
1. Lewold et al (1998) Revision of unicompartmental knee arthroplasty: outcome in 1,135 cases from the Swedish Knee Arthroplasty study. Acta Orthop Scand. 69(5):469-74.
2. Kalra et al (2011) Assessment of radiolucent lines around the Oxford unicompartmental knee replacement: sensitivity and specificity for loosening. J Bone Joint Surg Br. 93(6):777-81.
3. Thompson, et al (2010) The Importance of a Good Cement Mantle with an All-Poly Inlay UKA. ORS. New Orleans, USA
4. Goldstein (2007) Improvement of cement mantle thickness with pressurized carbon dioxide lavage. ISTA. Paris, France.
5. Woodgate (2008) A radiological comparison of cement mantle thickness around TKA with or without the use of pressurized carbon dioxide lavage. Australian Orthopaedic Association.
6. Ravenscroft (2010) Bone-Cement Interface Strength in Distal Radii Using Two Medullary Canal Preparation Techniques. Hand Surgery 15 (2): 95-98.
7. Jones RE (2011) Total Knee Arthroplasty Without the Use of a Tourniquet. Seminars in Arthroplasty 22(3):176.



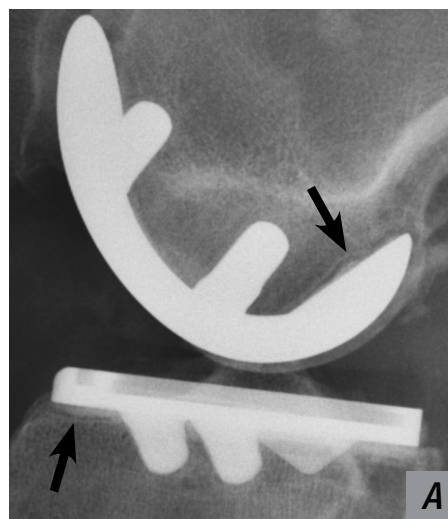
Patient A – Bone bed prepared with pulsatile saline lavage. Arrow indicates radiolucent line.



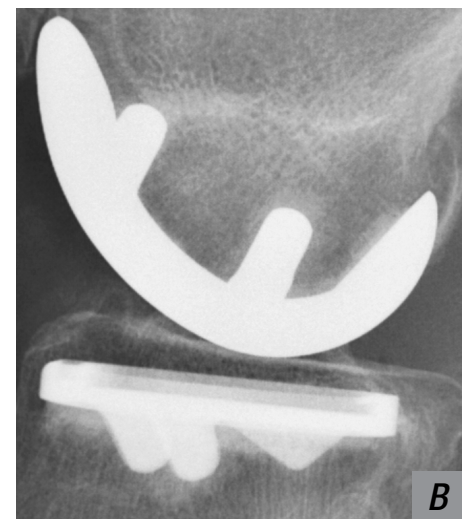Patient B – Bone bed prepared with syringe saline lavage and CarboJet CO₂ Bone Preparation System.



The CarboJet nozzle provides good access for cleaning and drying posterior aspects of both the tibial and femoral surfaces.



Patient A – Bone bed prepared with pulsatile saline lavage. Arrows indicate radiolucent lines.



Patient B – Bone bed prepared with syringe saline lavage and CarboJet CO₂ Bone Preparation System.



Expect Innovation.

www.kinamed.com