

Technique Using Isoelastic Tension Band for Treatment of Olecranon Fractures

Rebecca A. Rajfer, MD, Jonathan R. Danoff, MD, Kiran S. Yemul, MHS, Ioannis Zouzias, MD, and Melvin P. Rosenwasser, MD

Free article from AMJorthopedics.com downloaded and printed on Dec 11, 2015.

To view the original article online, and see a video demonstration click [here](#) or scan the QR code at right.



Abstract

The isoelastic ultrahigh-molecular-weight polyethylene tension band may be considered an alternative to stainless steel wire for tension band fixation of olecranon fractures.

In this article, we present our technique using this isoelastic tension band and describe the outcomes of 7 patients who underwent open reduction and internal fixation of closed, displaced olecranon fractures with minimal or no articular surface comminution. We reviewed medical records and performed physical examinations and functional assessments.

Anatomical reduction was maintained in all elbows through union. Physical examination measurements indicated nominal side-to-side differences in motion and strength. Mean Broberg and Morrey elbow score was good (92/100), and mean (SD) Disabilities of the Arm, Shoulder, and Hand score was 12.6 (17.2). One patient had a minor degree of hardware irritation at longest follow-up but did not request hardware removal. One patient underwent implant removal for a symptomatic implant 5 years after surgery.

This easily reproducible technique yields excellent physical and functional outcomes.

Various modifications of the TBW technique of Weber and Vasey⁴ have been proposed to reduce the frequency of complications. These modifications include substituting screws for K-wires, aiming the angle of the K-wires into the anterior coronoid cortex or loop configuration of the stainless steel wire, using double knots and twisting procedures to finalize fixation, and using alternative materials for the loop construct.⁵⁻⁸ In the literature and in our experience, patients often complain after surgery about prominent K-wires and the twisted knots used to tension the construct.⁹⁻¹² Surgeons also must address the technical difficulties of positioning the brittle wire without kinking, and avoiding slack while tensioning.

In this article, we report on the clinical outcomes of a series of 7 patients with olecranon fracture treated with a US Food and Drug Administration–approved novel isoelastic ultrahigh-molecular-weight polyethylene (UHMWPE) cerclage cable (Iso-Elastic Cerclage System, Kinamed).

Materials and Methods

Surgical Technique

The patient is arranged in a sloppy lateral position to allow access to the posterior elbow. A nonsterile tourniquet is placed on the upper arm, and the limb is sterilely prepared and draped in standard fashion. A posterolateral incision is made around the olecranon and extended proximally 6 cm and distally 6 cm along the subcutaneous border of the ulna. The fracture is visualized and comminution identified.

To provide anchorage for a pointed reduction clamp, the surgeon drills a 2.5-mm hole in the subcutaneous border of the ulnar shaft. The fracture is reduced in extension and the clamp affixed. The elbow is then flexed and the reduction confirmed visually and by imaging. After realignment of the articular surfaces, 2 longitudinal, parallel K-wires (diameter, 1.6-2.0 mm) are passed in antegrade direction through the proximal olecranon within the medullary canal of the shaft. The proximal ends must not cross the cortex so they may fully capture the figure-of-8 wire during subsequent, final advancement, and the distal ends must not pierce the anterior cortex. A 2.5-mm transverse hole is created distal to the fracture in the dorsal aspect of the ulnar shaft from medial to lateral at 2 times the distance from the tip of the olecranon to the fracture

Olecranon fractures are relatively common in adults and constitute 10% of all upper extremity injuries.^{1,2} An olecranon fracture may be sustained either directly (from blunt trauma or a fall onto the tip of the elbow) or indirectly (as a result of forceful hyperextension of the triceps during a fall onto an outstretched arm). Displaced olecranon fractures with extensor discontinuity require reduction and stabilization. One treatment option is tension band wiring (TBW), which is used to manage noncomminuted fractures.³ TBW, first described by Weber and Vasey⁴ in 1963, involves transforming the distractive forces of the triceps into dynamic compression forces across the olecranon articular surface using 2 intramedullary Kirschner wires (K-wires) and stainless steel wires looped in figure-of-8 fashion.

Authors' Disclosure Statement: Kinamed funded production of the technique video.

site. This hole is expanded with a 3.5-mm drill bit, allowing both strands of the cable to be passed simultaneously medial to lateral, making the figure-of-8. The 3.5-mm hole represents about 20% of the overall width of the bone, which we have not found to create a significant stress riser in either laboratory or clinical tests of this construct. Proximally, the cables are placed on the periosteum of the olecranon but deep to the triceps tendon and adjacent to the K-wires. The locking clip is placed on the posterolateral aspect of the elbow joint in a location where it can be covered with local tissue for adequate padding. The cable is then threaded through the clamping bracket and tightened slowly and gradually with a tensioning device to low torque level (**Figure 1**). At this stage, tension may be released to make any necessary adjustments. Last, the locking clip is deployed, securing the tension band in the clip, and the excess cable is trimmed with a scalpel. Softening and pliability of

the cable during its insertion and tensioning should be noted.

The ends of the K-wires are now curved in a hook configuration. The tines of the hooks should be parallel to accommodate the cable, and then the triceps is sharply incised to bone. If the bone is hard, an awl is used to create a pilot hole so the hook may be impaled into bone while capturing the cable. Next, the triceps is closed over the pins, minimizing the potential for pin migration and backout. The 2 K-wires are left in place to keep the fragments in proper anatomical alignment during healing and to prevent displacement with elbow motion. **Figure 2** is a schematic of the final construct, and **Figure 3** shows the construct in a patient.

Reduction of the olecranon fracture is assessed by imaging in full extension to check for possible implant impingement. Last, we apply the previously harvested fracture callus to the fracture site. Layered closure is performed, and bulky

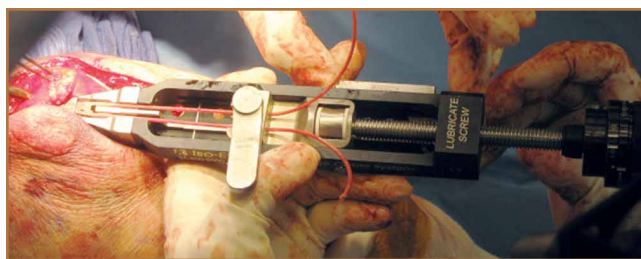


Figure 1. Isoelastic cerclage cable tensioning device.

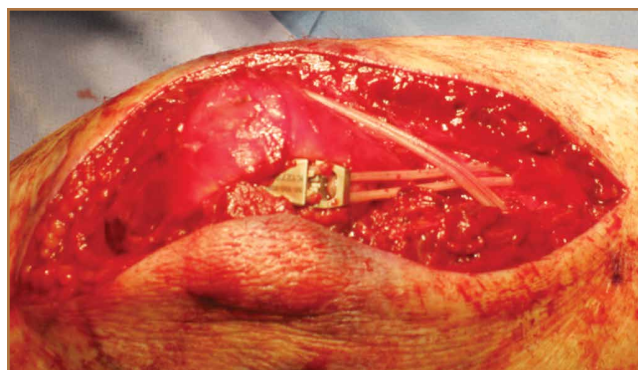


Figure 3. Final construct before closure. Note original fracture callus reapplied and posterolateral placement of clamping device.

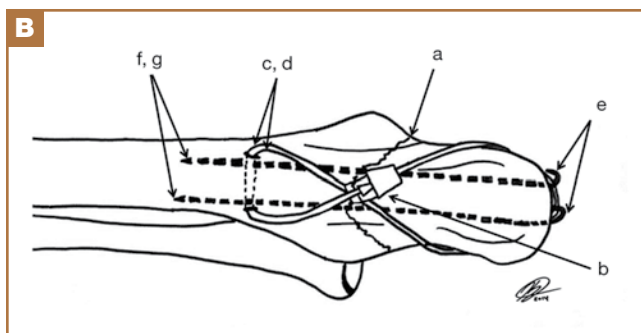
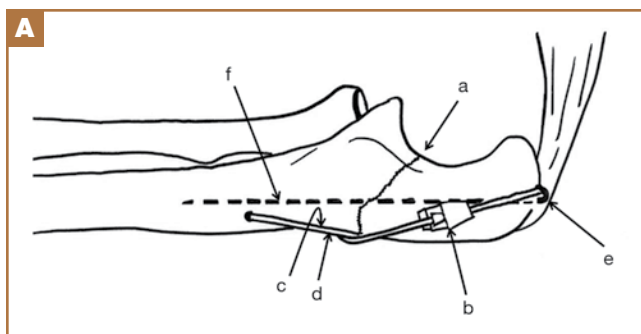


Figure 2. (A) Lateral and (B) posterior perspectives. Fracture line (a), locking clip (b), cables (c,d), Kirschner-wire hook under triceps (e), Kirschner wire in ulnar shaft (f,g).

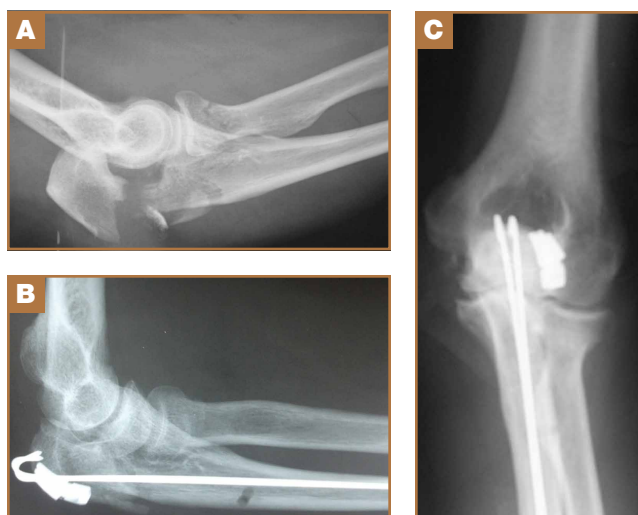

Figure 4. (A) Injury film. (B) Isoelastic tension band construct on anteroposterior radiograph at 3-month follow-up. Note radiolucency of cable and low-profile placement of clamping device. (C) Lateral radiograph at 3-month follow-up.

soft dressings are applied. Postoperative immobilization with a splint is used. Gentle range-of-motion exercises begin in about 2 weeks and progress as pain allows.

A case example with preoperative and postoperative images taken at 3-month follow-up is provided in **Figure 4**. The entire surgical technique can be viewed in the **Video**, which is available online at www.amjorthopedics.com.

Clinical Cases

Between July 2007 and February 2011, 7 patients with displaced olecranon fractures underwent osteosynthesis using the isoelastic tension band (**Table 1**). According to the Mayo classification system, 5 of these patients had type 2A fractures, 1 had a type 2B fracture with an ipsilateral nondisplaced radial neck fracture, and 1 had a type 3B fracture. There were 4 fe-

male and 3 male patients. The injury was on the dominant side in 3 patients. All patients gave informed consent to evaluation at subsequent office visits and completed outcomes questionnaires by mail several years after surgery. Mean follow-up at which outcome measures questionnaires were obtained was 3.3 years (range, 2.1-6.8 years). Exclusion criteria were age under 18 years and inability to provide informed consent, fracture patterns with extensive articular comminution, and open fractures. Permission to conduct this research was granted by institutional review board.

At each visit, patients completed the Disabilities of the Arm, Shoulder, and Hand (DASH) functional outcome survey and were evaluated according to Broberg and Morrey’s elbow scoring system.^{13,14} Chart review consisted of evaluation of medical records, including radiographs and orthopedic physician

Table 1. Patients' Baseline Characteristics

Patient	Sex	Age at Time of Surgery, y	Side of Injury	Dominant Hand	Mechanism of Injury	Mayo Fracture Classification
1	F	73	R	R	Ground-level fall	3B
2	M	19	R	R	Volleyball injury	2A
3	F	84	R	R	Slip and fall	2A
4	F	71	L	R	Trip and fall	2A
5	M	56	L	R	Fall from bike	2A
6	F	70	L	R	Ground-level fall	2A
7	M	66	L	R	Fall down flight of stairs	2B with radial neck fracture
Mean (SD)		62.7 (21.0)				

Table 2. Physical Examination Measurements, Healing Time, and Patient-Rated Outcome Measures

Patient	Physical Examination Measurements and Healing Time					Patient-Rated Outcome Measures				
	Flexion Arc, %	Forearm Arc, %	Grip Strength, %	Longest ROM Follow-Up, mo	Days to Union	B&M	DASH	VAS Pain	VAS Satisfaction	Longest Subjective Measure Follow-Up, y
1	20/90 (22)	90/180 (80)	20/30 (66)	5.0	220	80.5	40.5	0.0	10.0	6.79
2 ^a	150/150 (100)	165/180 (92)	41/39 (105)	31	55	100	0.0	2.0	10.0	2.57
3	145/145 (100)	175/175 (100)	16/11 (146)	29	48	93	34.5	0.5	10.0	2.49
4	125/135 (92)	175/180 (97)	23/19 (121)	28	78	98	2.5	0.0	10.0	2.36
5	135/135 (100)	180/170 (106)	49/53 (92)	25	69	100	0.0	0.0	9.5	2.14
6	120/135 (89)	180/175 (102)	24/34 (71)	12	78	82	3.6	0.0	9.5	3.65
7	130/135 (96)	175/180 (97)	37/38 (97)	3.0	49	92	7.5	3.0	10.0	2.98
Mean	96%	96%	99%	19	85.3	92.2	12.6	0.79	9.8	3.3

Abbreviations: B&M, Broberg and Morrey elbow score; DASH, Disabilities of the Arm, Shoulder, and Hand; ROM, range of motion; VAS, visual analog scale.

^aHad symptomatic implant removed 5 years after surgery.

notes in which preoperative examination was documented, mechanism of injury was noted, radiologic fracture pattern was evaluated, and time to bony union was recorded. Elbow motion was documented. Grip strength was measured with a calibrated Jamar dynamometer (Sammons Preston Rolyan) set at level 2, as delineated in Broberg and Morrey's functional elbow scoring system.

Results

The 7 patients were assessed at a mean final follow-up of 19 months after surgery and received a mean Broberg and Morrey score of *good* (92.2/100) (Table 2). Restoration of motion and strength was excellent; compared with contralateral extremity, mean flexion arc was 96%, and mean forearm rotation was 96%. Grip was 99% of the noninjured side, perhaps the result of increased conditioning from physical therapy. Patients completed outcomes questionnaires at a mean of 3.3 years after surgery. Mean (SD) DASH score at this longest follow-up was 12.6 (17.2) (Table 2). Patients were satisfied (mean, 9.8/10; range, 9.5-10) and had little pain (mean, 0.8/10; range, 0-3). All fractures united, and there were no infections. One patient had a satisfactory union with complete restoration of motion and continued to play sports vocationally but developed pain over the locking clip 5 years after the index procedure and decided to have the implant removed. He had no radiographic evidence of K-wire or implant migration. Another patient had a minor degree of implant irritation at longest follow-up but did not request hardware removal.

Discussion

Stainless steel wire is often used in TBW because of its widespread availability, low cost, lack of immunogenicity, and relative strength.⁷ However, stainless steel wire has several disadvantages. It is susceptible to low-cycle fatigue failure, and fatigue strength may be seriously reduced secondary to incidental trauma to the wire on implantation.^{15,16} Other complications are kinking, skin irritation, implant prominence, fixation loss caused by wire loosening, and inadequate initial reduction potentially requiring revision.^{10,12,17-21}

Isoelastic cable is a new type of cerclage cable that consists of UHMWPE strands braided over a nylon core. The particular property profile of the isoelastic tension band gives the cable intrinsic elastic and pliable qualities. In addition, unlike stainless steel, the band maintains a uniform, continuous compression force across a fracture site.²² Multifilament braided cables fatigue and fray, but the isoelastic cerclage cable showed no evidence of fraying or breakage after 1 million loading cycles.^{22,23} Compared with metal wire or braided metal cable, the band also has higher fatigue strength and higher ultimate tensile strength.⁷ Furthermore, the cable is less abrasive than stainless steel, so theoretically it is less irritating to surrounding subcutaneous tissue. Last, the pliability of the band allows the surgeon to create multiple loops of cable without the wire-failure side effects related to kinking, which is common with the metal construct.

In 2010, Ting and colleagues²⁴ retrospectively studied im-

plant failure complications associated with use of isoelastic cerclage cables in the treatment of periprosthetic fractures in total hip arthroplasty. They reported a breakage rate of 0% and noted that previously published breakage data for metallic cerclage devices ranged from 0% to 44%. They concluded that isoelastic cables were not associated with material failure, and there were no direct complications related to the cables. Similarly, Edwards and colleagues²⁵ evaluated the same type of cable used in revision shoulder arthroplasty and reported excellent success and no failures. Although these data stem from use in the femur and humerus, we think the noted benefits apply to fractures of the elbow as well, as we observed a similar breakage rate (0%).

Various studies have addressed the clinical complaints and reoperation rates associated with retained metal implants after olecranon fixation. Traditional AO (Arbeitsgemeinschaft für Osteosynthesefragen) technique involves subcutaneous placement of stainless steel wires, which often results in tissue irritation. Reoperation rates as high as 80% have been reported, and a proportion of implant removals may in fact be caused by factors related to the subcutaneous placement of the metallic implants rather than K-wire migration alone.^{5,12,18} A nonmetallic isoelastic tension band can provide a more comfortable and less irritating implant, which could reduce the need for secondary intervention related to painful subcutaneous implant. One of our 7 patients had a symptomatic implant removed 5 years after surgery. This patient complained of pain over the area of the tension band device clip, so after fracture healing the entire fixation device was removed in the operating room. If reoperation is necessary, removal of intramedullary K-wires is relatively simple using a minimal incision; removal of stainless steel TBW may require a larger approach if the twisted knots cannot be easily retrieved.

A study of compression forces created by stainless steel wire demonstrated that a "finely tuned mechanical sense" was needed to produce optimal fixation compression when using stainless steel wire.²⁶ It was observed that a submaximal twist created insufficient compressive force, while an ostensibly minimal increase in twisting force above optimum abruptly caused wire failure through breakage. Cerclage cables using clasp devices, such as the current isoelastic cerclage cable, were superior in ease of application. Furthermore, a clasp device allows for cable tension readjustment that is not possible with stainless steel wire. The clasp mechanism precludes the surgeon from having to bury the stainless steel knot and allows for the objective cable-tensioning not possible with stainless steel wire. Last, the tensioning device is titratable, which allows the surgeon to set the construct at a predetermined quantitative tension, which is of benefit in patients with osteopenia.

One limitation of this study is that it did not resolve the potential for K-wire migration, and we agree with previous recommendations that careful attention to surgical technique may avoid such a complication.¹⁰ In addition, the sample was small, and the study lacked a control group; a larger sample and a control group would have boosted study power. Neverthe-

less, the physical and functional outcomes associated with use of this technique were excellent. These results demonstrate an efficacious attempt to decrease secondary surgery rates and are therefore proof of concept that the isoelastic tension band may be used as an alternative to stainless steel in the TBW of displaced olecranon fractures with minimal or no comminution.

Conclusion

This easily reproducible technique for use of an isoelastic tension band in olecranon fracture fixation was associated with excellent physical and functional outcomes in a series of 7 patients. The rate of secondary intervention was slightly better for these patients than for patients treated with wire tension band fixation. Although more rigorous study of this device is needed, we think it is a promising alternative to wire tension band techniques.

Dr. Rajfer is Postdoctoral Residency Fellow, Department of Orthopaedic Surgery, George Washington University Medical Center, Washington, DC. Dr. Danoff is Postdoctoral Residency Fellow, Department of Orthopedic Surgery, Columbia University Medical Center, New York, New York. Ms. Yemul is Research Program Coordinator, Center for Surgical Trials and Outcomes Research, Department of Surgery, Johns Hopkins University School of Medicine, Baltimore, Maryland. Dr. Zouzias is Attending Orthopedic Surgeon, Winthrop-University Hospital, Garden City, New York. Dr. Rosenwasser is Attending Orthopedic Surgeon and Chief of Trauma, Department of Orthopedic Surgery, Columbia University Medical Center, New York, New York.

Acknowledgments: Data from this study were presented as an e-poster at the annual American Society for Surgery of the Hand (ASSH) Adrian E. Flatt Residents and Fellows Conference in Hand Surgery, September 2011, Las Vegas, Nevada, and on the podium at the annual meeting of the American Association for Hand Surgery (AAHS), January 2012, Las Vegas, Nevada.

Address correspondence to: Melvin P. Rosenwasser, MD, Department of Orthopedic Surgery, Columbia University College of Physicians and Surgeons, 622 W 168th St, PH11-1164, New York, NY 10032 (tel, 212-305-3912; fax, 212-342-1749; email, ttc@columbia.edu).

Am J Orthop. 2015;44(12):542-546. Copyright Frontline Medical Communications Inc. 2015. All rights reserved.

References

1. Rommens PM, Küchle R, Schneider RU, Reuter M. Olecranon fractures in adults: factors influencing outcome. *Injury.* 2004;35(11):1149-1157.
2. Veillette CJ, Steinmann SP. Olecranon fractures. *Orthop Clin North Am.* 2008;39(2):229-236.
3. Newman SD, Mauffrey C, Krikler S. Olecranon fractures. *Injury.* 2009;40(6):575-581.

4. Weber BG, Vasey H. Osteosynthesis in olecranon fractures [in German]. *Z Unfallmed Berufskr.* 1963;56:90-96.
5. Netz P, Strömberg L. Non-sliding pins in traction absorbing wiring of fractures: a modified technique. *Acta Orthop Scand.* 1982;53(3):355-360.
6. Prayson MJ, Williams JL, Marshall MP, Sclaris TA, Lingenfelter EJ. Biomechanical comparison of fixation methods in transverse olecranon fractures: a cadaveric study. *J Orthop Trauma.* 1997;11(8):565-572.
7. Rothaug PG, Boston RC, Richardson DW, Nunamaker DM. A comparison of ultra-high-molecular weight polyethylene cable and stainless steel wire using two fixation techniques for repair of equine midbody sesamoid fractures: an in vitro biomechanical study. *Vet Surg.* 2002;31(5):445-454.
8. Harrell RM, Tong J, Weinhold PS, Dahners LE. Comparison of the mechanical properties of different tension band materials and suture techniques. *J Orthop Trauma.* 2003;17(2):119-122.
9. Nimura A, Nakagawa T, Wakabayashi Y, Sekiya I, Okawa A, Muneta T. Repair of olecranon fractures using FiberWire without metallic implants: report of two cases. *J Orthop Surg Res.* 2010;5:73.
10. Macko D, Szabo RM. Complications of tension-band wiring of olecranon fractures. *J Bone Joint Surg Am.* 1985;67(9):1396-1401.
11. Helm RH, Hornby R, Miller SW. The complications of surgical treatment of displaced fractures of the olecranon. *Injury.* 1987;18(1):48-50.
12. Romero JM, Miran A, Jensen CH. Complications and re-operation rate after tension-band wiring of olecranon fractures. *J Orthop Sci.* 2000;5(4):318-320.
13. Beaton DE, Katz JN, Fossel AH, Wright JG, Tarasuk V, Bombardier C. Measuring the whole or the parts? Validity, reliability, and responsiveness of the Disabilities of the Arm, Shoulder and Hand outcome measure in different regions of the upper extremity. *J Hand Ther.* 2001;14(2):128-146.
14. Broberg MA, Morrey BF. Results of delayed excision of the radial head after fracture. *J Bone Joint Surg Am.* 1986;68(5):669-674.
15. Bostrom MP, Asnis SE, Ernberg JJ, et al. Fatigue testing of cerclage stainless steel wire fixation. *J Orthop Trauma.* 1994;8(5):422-428.
16. Oh I, Sander TW, Trehan RW. The fatigue resistance of orthopaedic wire. *Clin Orthop Relat Res.* 1985;(192):228-236.
17. Amstutz HC, Maki S. Complications of trochanteric osteotomy in total hip replacement. *J Bone Joint Surg Am.* 1978;60(2):214-216.
18. Jensen CM, Olsen BB. Drawbacks of traction-absorbing wiring (TAW) in displaced fractures of the olecranon. *Injury.* 1986;17(3):174-175.
19. Kumar G, Mereddy PK, Hakkalamani S, Donnachie NJ. Implant removal following surgical stabilization of patella fracture. *Orthopedics.* 2010;33(5).
20. Hume MC, Wiss DA. Olecranon fractures. A clinical and radiographic comparison of tension band wiring and plate fixation. *Clin Orthop Relat Res.* 1992;(285):229-235.
21. Wolfgang G, Burke F, Bush D, et al. Surgical treatment of displaced olecranon fractures by tension band wiring technique. *Clin Orthop Relat Res.* 1987;(224):192-204.
22. Sarin VK, Mattchen TM, Hack B. A novel iso-elastic cerclage cable for treatment of fractures. Paper presented at: Annual Meeting of the Orthopaedic Research Society; February 20-23, 2005; Washington, DC. Paper 739.
23. Silvertown CD, Jacobs JJ, Rosenberg AG, Kull L, Conley A, Galante JO. Complications of a cable grip system. *J Arthroplasty.* 1996;11(4):400-404.
24. Ting NT, Wera GD, Levine BR, Della Valle CJ. Early experience with a novel nonmetallic cable in reconstructive hip surgery. *Clin Orthop Relat Res.* 2010;468(9):2382-2386.
25. Edwards TB, Stuart KD, Trappey GJ, O'Connor DP, Sarin VK. Utility of polymer cerclage cables in revision shoulder arthroplasty. *Orthopedics.* 2011;34(4).
26. Shaw JA, Daubert HB. Compression capability of cerclage fixation systems. A biomechanical study. *Orthopedics.* 1988;11(8):1169-1174.

This paper will be judged for the Resident Writer's Award.