



This is an enhanced PDF from The Journal of Bone and Joint Surgery

The PDF of the article you requested follows this cover page.

Custom Patellofemoral Arthroplasty of the Knee. Surgical Technique

Domenick J. Sisto and Vineet K. Sarin

J Bone Joint Surg Am. 2007;89:214-225. doi:10.2106/JBJS.G.00186

This information is current as of September 3, 2007

Reprints and Permissions

Click here to [order reprints or request permission](#) to use material from this article, or locate the article citation on jbjs.org and click on the [Reprints and Permissions] link.

Publisher Information

The Journal of Bone and Joint Surgery
20 Pickering Street, Needham, MA 02492-3157
www.jbjs.org

Custom Patellofemoral Arthroplasty of the Knee

Surgical Technique

By Domenick J. Sisto, MD, and Vineet K. Sarin, PhD

Investigation performed at Los Angeles Orthopaedic Institute, Sherman Oaks, California

The original scientific article in which the surgical technique was presented was published in JBJS Vol. 88-A, pp. 1475-80, July 2006

ABSTRACT FROM THE ORIGINAL ARTICLE

BACKGROUND: The treatment of isolated patellofemoral arthritis is controversial. Several surgical procedures have been used to treat the severely degenerated patellofemoral joint, with varying degrees of success. The purpose of this study was to determine the clinical results of a custom patellofemoral arthroplasty for the treatment of isolated patellofemoral degenerative arthritis of the knee.

METHODS: From 1995 through 2002, twenty-five patellofemoral replacements, three of which were bilateral, were performed in twenty-two patients for the treatment of isolated patellofemoral arthritis of the knee. According to the Ahlback radiographic evaluation scale, the mean preoperative score for the severity of the arthritis was 4.65 points in the patellofemoral compartment and 0.5 point in both the medial and the lateral compartment. The patients included sixteen women (two of whom had a bilateral replacement) and six men (one of whom had a bilateral replacement) with a mean age of forty-five years at the time of the index arthroplasty. Seventeen patients (nineteen knees) had had a prior procedure on the knee. The mean preoperative Knee Society functional score was 49 points, and the mean preoperative Knee Society objective score was 52 points.

RESULTS: At a mean of seventy-three months (range, thirty-two to 119 months) postoperatively, all twenty-five implants were in place and functioning well. There were eighteen excellent and seven good results. The mean Knee Society functional score was 89 points, and the mean Knee Society objective score was 91 points. No patient had required additional surgery or had component loosening.

CONCLUSIONS: On the basis of our relatively short-term follow-up study, custom patellofemoral arthroplasty appears to be a safe and effective treatment for isolated patellofemoral arthritis of the knee. We believe that the results presented in this paper justify the additional cost associated with the custom device.

LEVEL OF EVIDENCE: Therapeutic Level IV. See Instructions to Authors for a complete description of levels of evidence.

ORIGINAL ABSTRACT CITATION: "Custom Patellofemoral Arthroplasty of the Knee" (2006;88:1475-80).

DISCLOSURE: The authors did not receive any outside funding or grants in support of their research for or preparation of this work. One or more of the authors, or a member of his or her immediate family, received, in any one year, payments or other benefits in excess of \$10,000 or a commitment or agreement to provide such benefits from a commercial entity (i.e., is an employee of [receives salary from] Kinamed, Inc.). No commercial entity paid or directed, or agreed to pay or direct, any benefits to any research fund, foundation, division, center, clinical practice, or other charitable or nonprofit organization with which the authors, or a member of their immediate families, are affiliated or associated.



A video supplement to this article will be available from the *Video Journal of Orthopaedics*. A video clip will be available at the JBJS web site, www.jbjs.org. The *Video Journal of Orthopaedics* can be contacted at (805) 962-3410, web site: www.vjortho.com.

**FIG. 1**

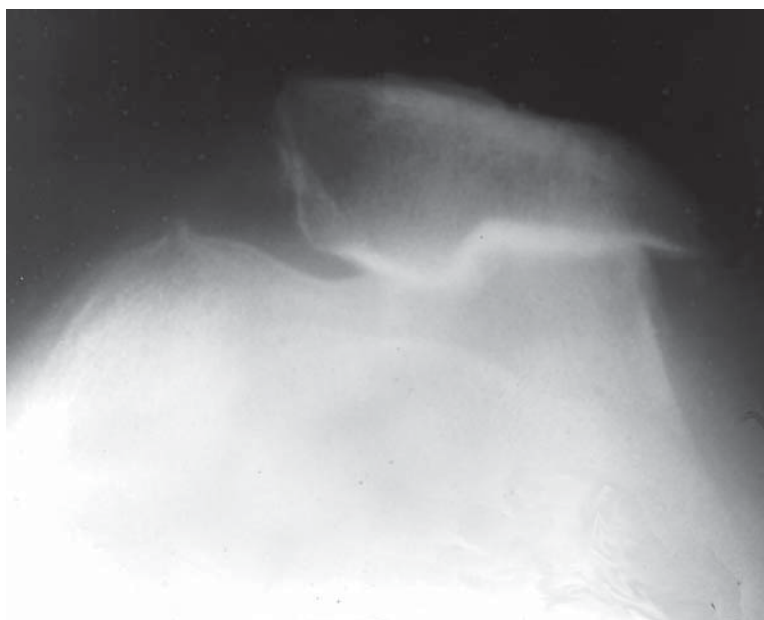
Custom patellofemoral prosthesis implanted on femur along with a patellar button.

INTRODUCTION

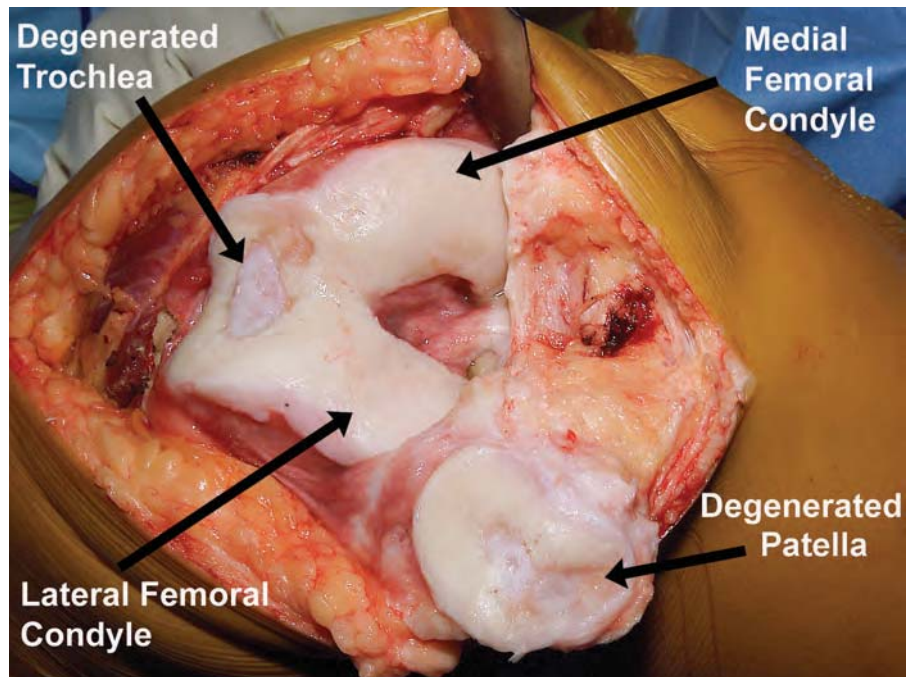
Custom patellofemoral arthroplasty prostheses are designed to

preserve the patellofemoral joint and address the inherent problems associated with so-called off-

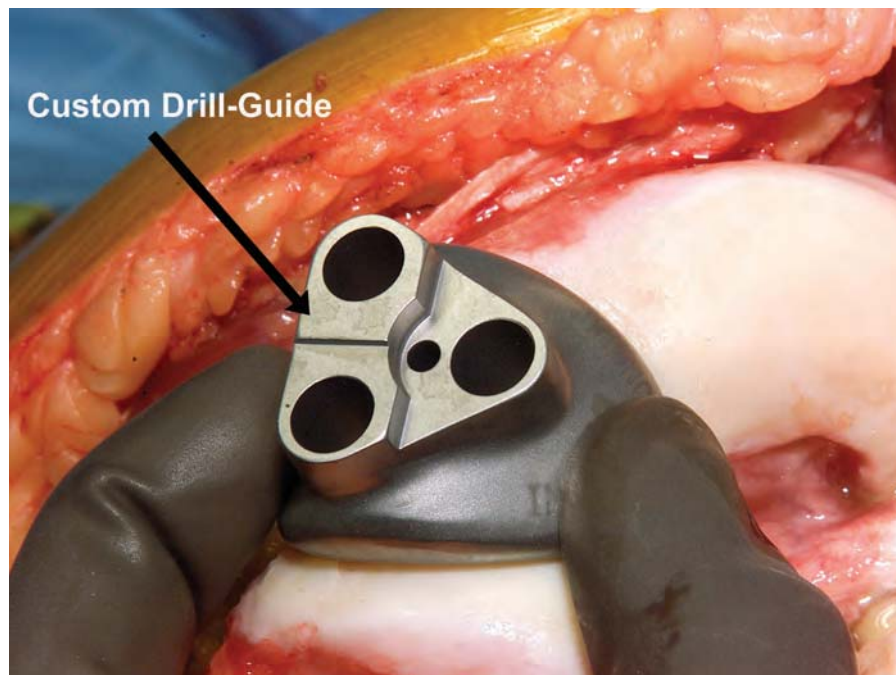
the-shelf patellofemoral prosthesis designs. The custom patellofemoral prosthesis described here (Fig. 1) does not require femoral bone resection because computed tomographic modeling is used to achieve a custom fit to the femoral anatomy of the patient. In order to prepare holes for the implant pegs, a small amount of femoral bone is removed with use of a drill. The prosthesis is designed to approximate normal kinematics by reestablishing the alignment and depth of the trochlear groove and to improve quadriceps function by repositioning the patella anteriorly. The thickness of the patellofemoral arthroplasty implant along the patellar tracking arc is designed to reestablish the native anterior position of the femur. The distal margin of the implant

**FIG. 2**

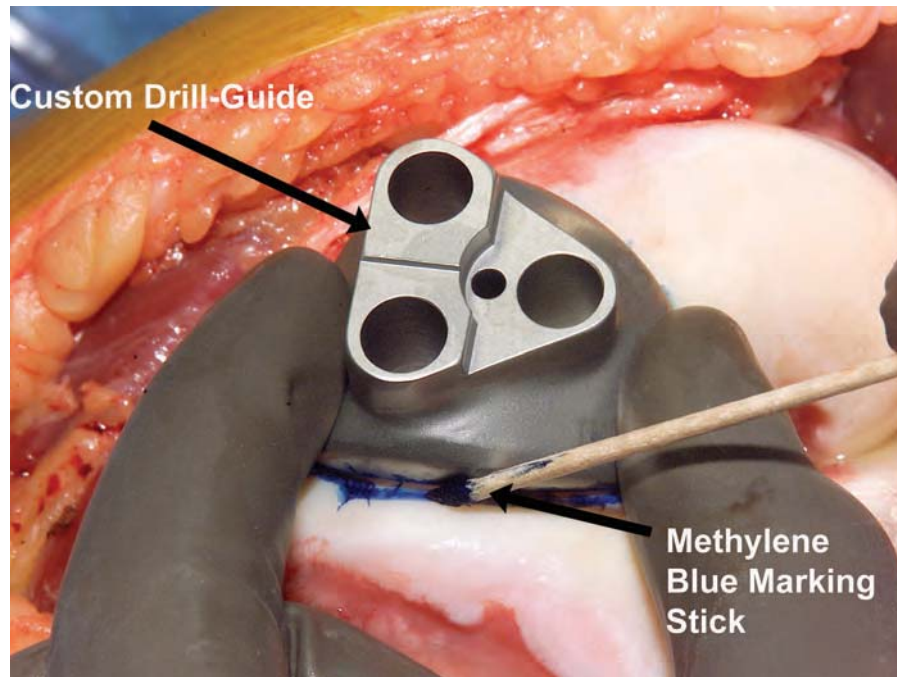
Preoperative Merchant-view radiograph showing degenerated patellofemoral joint.

**FIG. 3**

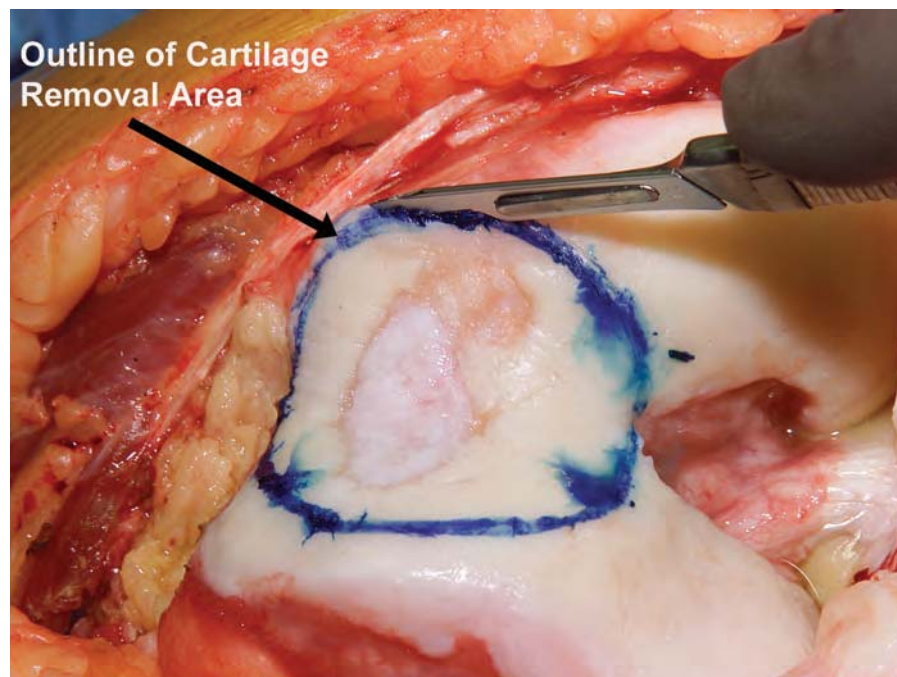
Intraoperative photograph showing cartilage degeneration isolated to the patellofemoral articulation.

**FIG. 4**

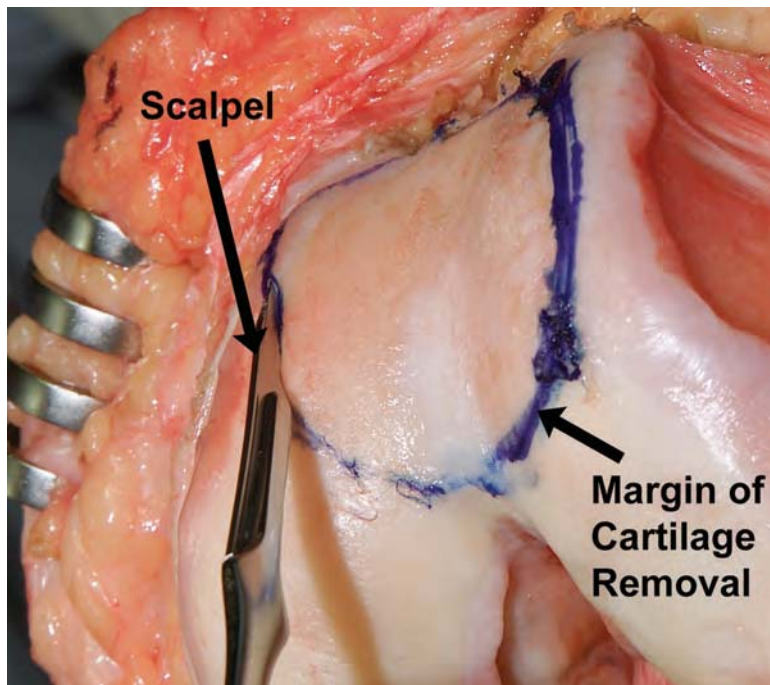
The custom drill-guide is used to assess the approximate fit of the implant onto the femoral groove.

**FIG. 5**

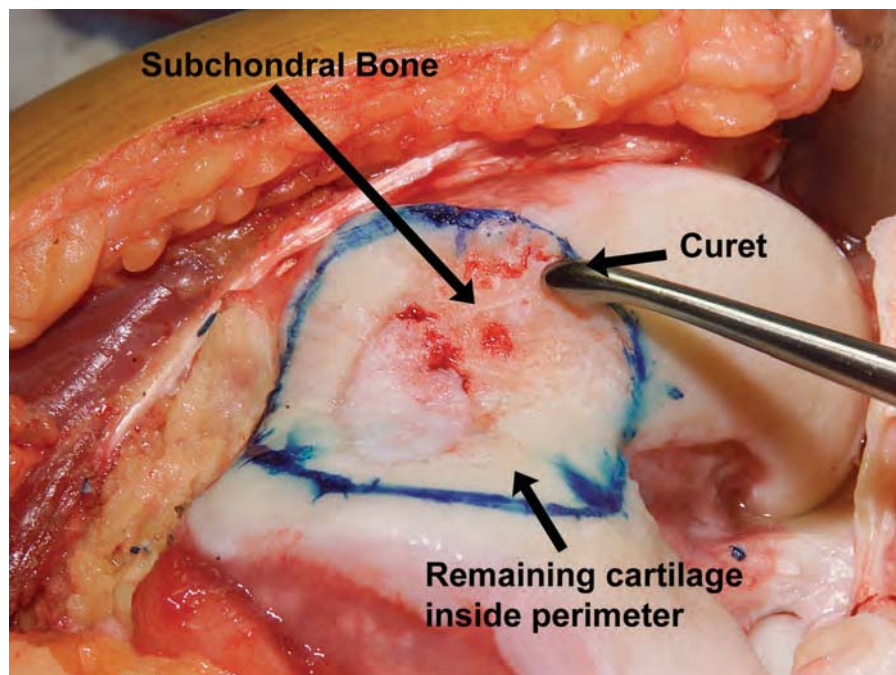
The custom drill-guide is used to mark the perimeter for cartilage removal.

**FIG. 6**

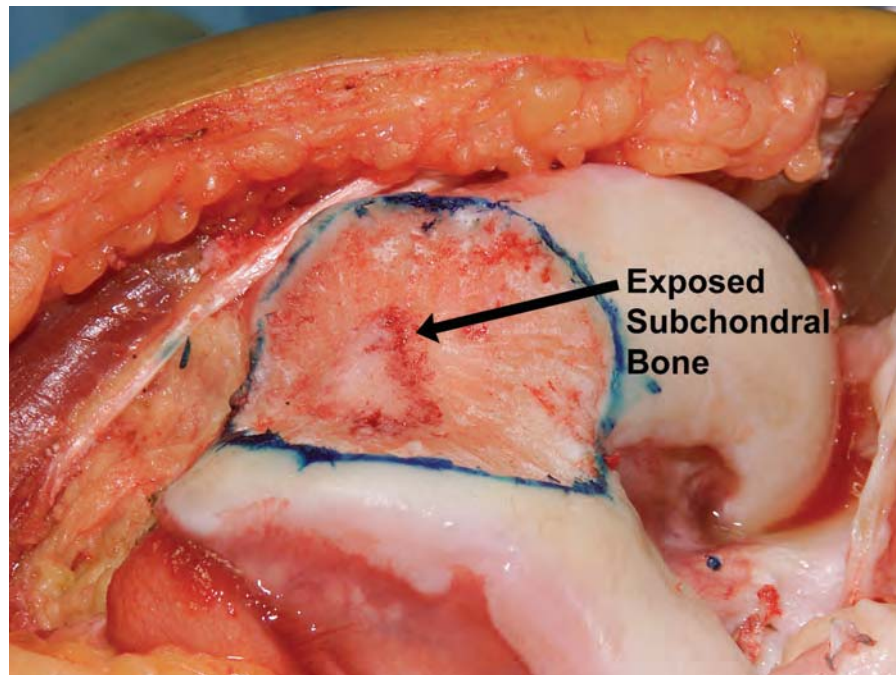
Perimeter for cartilage removal has been marked with methylene blue.

**FIG. 7**

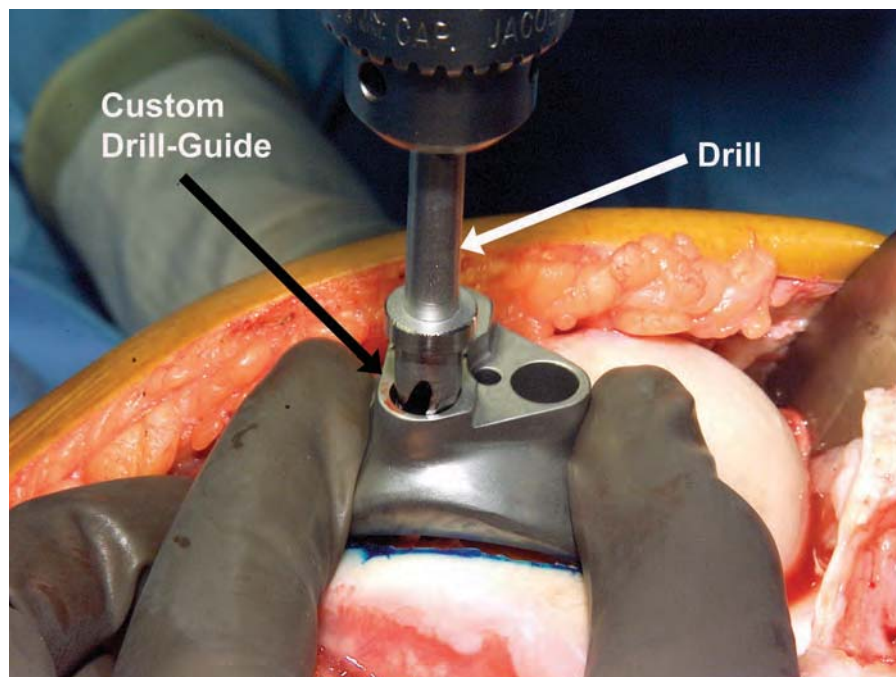
A scalpel is used to define the margin of the cartilage removal.

**FIG. 8**

A curet is employed to completely remove the remaining articular cartilage within the outlined margin, exposing the subchondral bone.

**FIG. 9**

Exposed subchondral bone inside the perimeter.

**FIG. 10**

With the drill-guide correctly positioned on the bone, three holes are drilled through the guide holes with an 8-mm stop drill.

is designed to rest 3 to 5 mm proximal to the apex of the femoral intercondylar notch. The femoral implant has a thickened lateral border to compensate for bone loss along the lateral edge of the trochlear groove and to provide congruency and tracking stability with the patellar implant. The purpose of this article is to describe the surgical technique of custom patellofemoral arthroplasty.

SURGICAL TECHNIQUE

Preoperative Planning

A computed tomography scan is performed according to specific instructions provided by the manufacturer of the Kine-Match prosthesis (Kinamed, Camarillo, California); the parameters include 120 to 140 kV,

FIG. 11

After the first hole is drilled, an alignment pin is inserted in the hole to stabilize the position of the drill-guide before the next two holes are prepared.

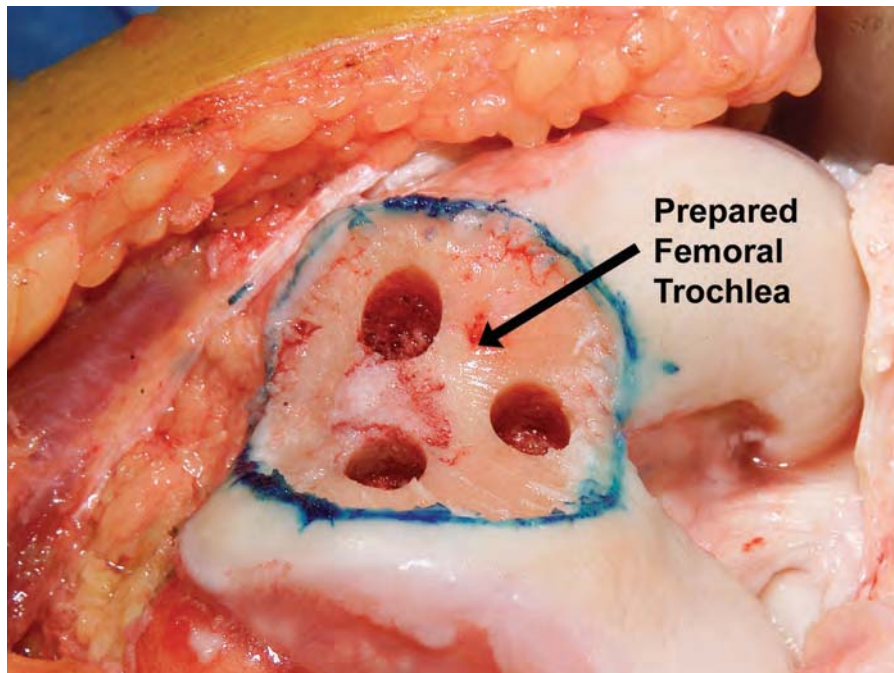
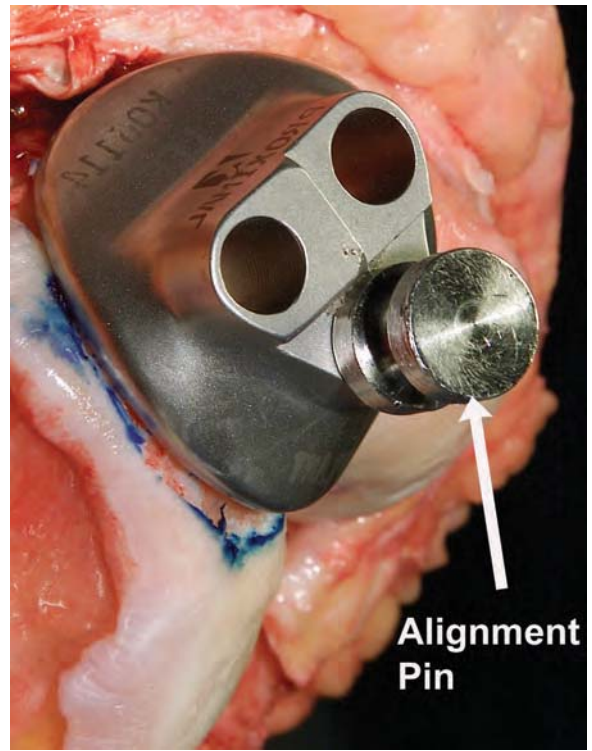


FIG. 12

The drilled holes have been thoroughly irrigated, and suction has been applied to remove bone particles and fluid.

200 to 300 mA, and a scan region of 5 mm distal to the femoral condyles to 10 mm proximal to the patella. Prior to the operation, the surgeon receives a computed tomography-reconstructed bone model of the distal part of the femur for review. He or she then uses the model to determine the need for osteophyte removal and communicates this to the implant manufacturer by physically sculpting the bone model and returning it to the manufacturer prior to the final implant design. Figure 2 demonstrates severe patellofemoral arthritis in a surgical candidate.

Preparation of the Femur

Intravenous antibiotics are administered preoperatively, and a tourniquet is utilized. A standard midline incision (typically 12 to 15 cm in length) is made, and a medial parapatellar arthrotomy is used to expose the patellofemoral trochlea (Fig. 3). The patella is everted. Because the computed tomography data from which the implant is created models bone and not cartilage, a proper fit is achieved by excision of only the overlying articular cartilage. The custom drill-guide is used to assess the approximate fit of the implant onto the femoral groove (Fig. 4) and to outline the area of cartilage removal (Figs. 5 and 6), which is then marked with a scalpel (Fig. 7). A curet is employed to completely remove the remaining articular cartilage within this outlined area, thus

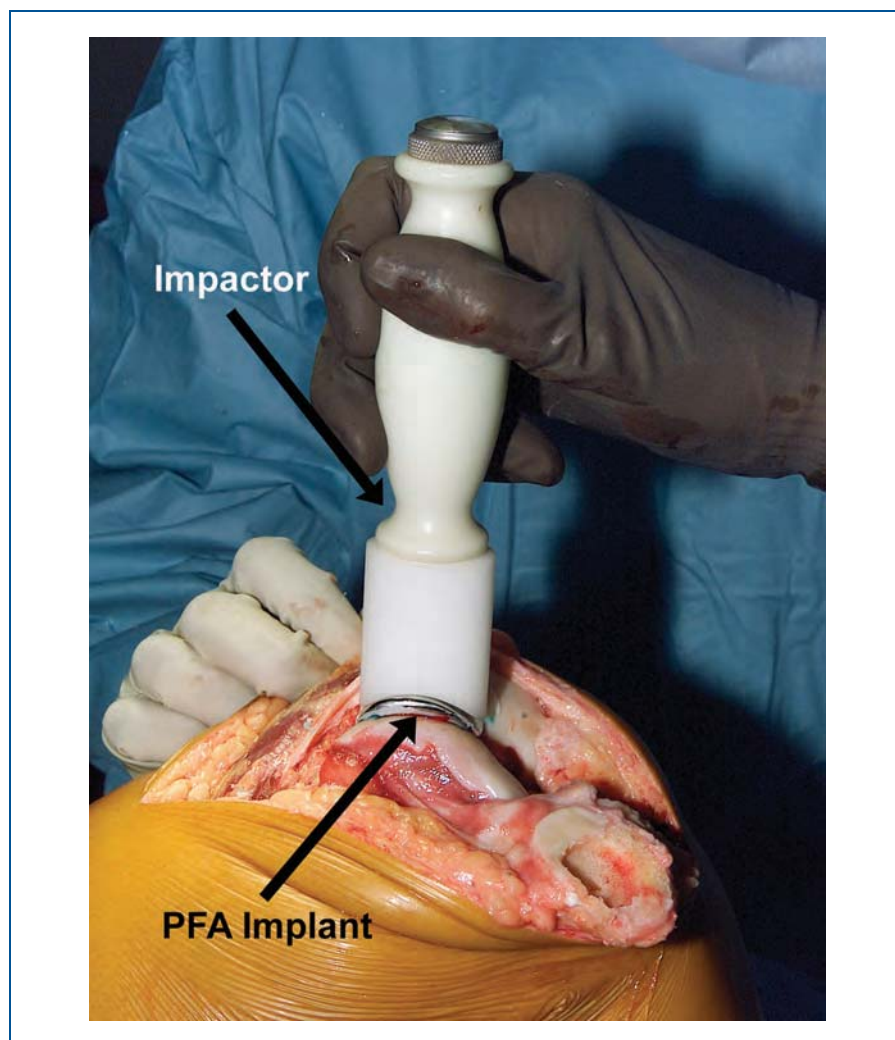

FIG. 13

Bone cement is prepared and injected into the drilled holes in the distal part of the femur, and the femoral implant is cemented and impacted into place. PFA = patellofemoral arthroplasty.

exposing the subchondral bone (Figs. 8 and 9). To determine the exact fit of the patellofemoral arthroplasty implant, the custom drill-guide is then moved across the distal part of the femur until it reaches a natural fit, as it does with the computed tomography bone model. With the drill-guide correctly positioned on the bone, three holes are drilled through the guide

holes with an 8-mm stop drill (Fig. 10). After the first hole is drilled, an alignment pin is inserted to stabilize the position of the drill-guide before the next two holes are prepared (Fig. 11). The drill holes are thoroughly irrigated, and suction is applied to remove bone particles and fluid (Fig. 12). The osseous bed of the distal part of the femur is prepared

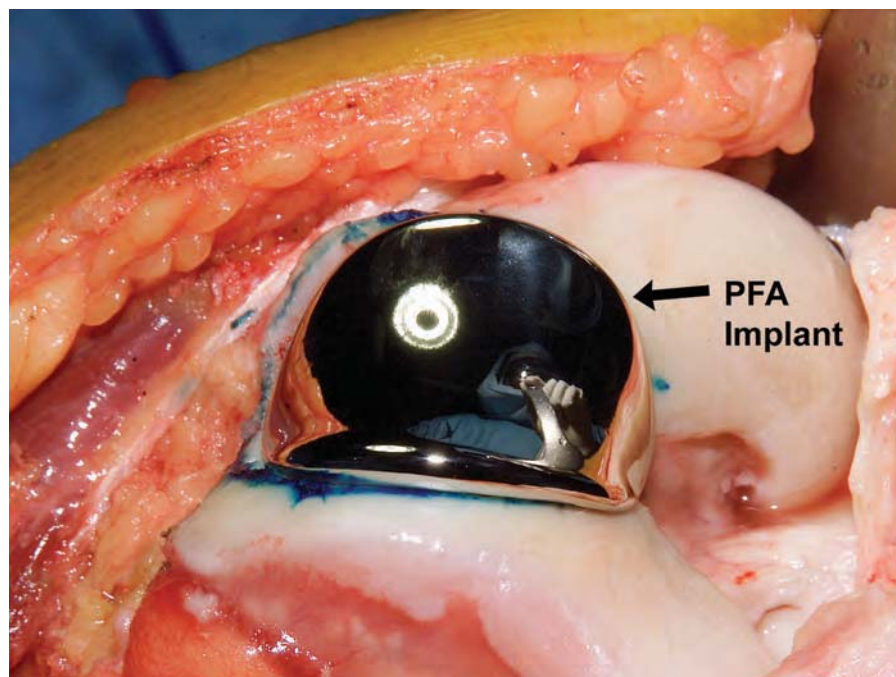


FIG. 14

The appearance of the patellofemoral implant after it has been cemented in place. PFA = patellofemoral arthroplasty.

to receive bone cement. The patellofemoral arthroplasty implant is trial-fitted by placing the implant pegs into the prepared holes and finding the natural fit of the implant on the femoral trochlea.

Preparation of the Patella

The patellofemoral arthroplasty implant is designed to articulate with a standard all-polyethylene domed patellar component. We select the component (either inset or onlay) so that the residual patellar bone has a thickness of ≥ 15 mm after resection, thus maintaining the overall patellar thickness with the implant in place. An attempt is made to match the final thickness of the patella-implant construct to its native thickness.

Implantation

Bone cement is prepared and injected into the drilled holes in the distal portion of the femur, and the femoral implant is then cemented in place (Figs. 13 and 14). The patellar implant is also secured with cement and is held in position by the patellar clamp until the cement has cured. The patella is then reduced to its anatomic position, and the implants are tested through a range of motion to ascertain that patellar tracking is anatomic; soft-tissue releases are performed as needed. To determine that patellar stability is adequate, the “no thumb” test of patellar tracking is used as a guide. Before the capsule is closed, the patella is observed as it articulates with the femoral trochlea during the

entire range of knee motion. Patellofemoral tracking is considered adequate when the patellar implant tracks congruently and centrally with minimal or no pressure applied to the lateral side of the patella. A lateral patellar retinacular release¹ is done when the patella subluxates laterally during the “no thumb” test. The arthrotomy site is then closed without the use of drains. Postoperative radiographs are examined for proper fit and alignment of the implants (Figs. 15-A, 15-B, and 15-C).

Postoperative Rehabilitation

Patients are not given prophylaxis against deep venous thrombosis because there is no violation or reaming of the fem-

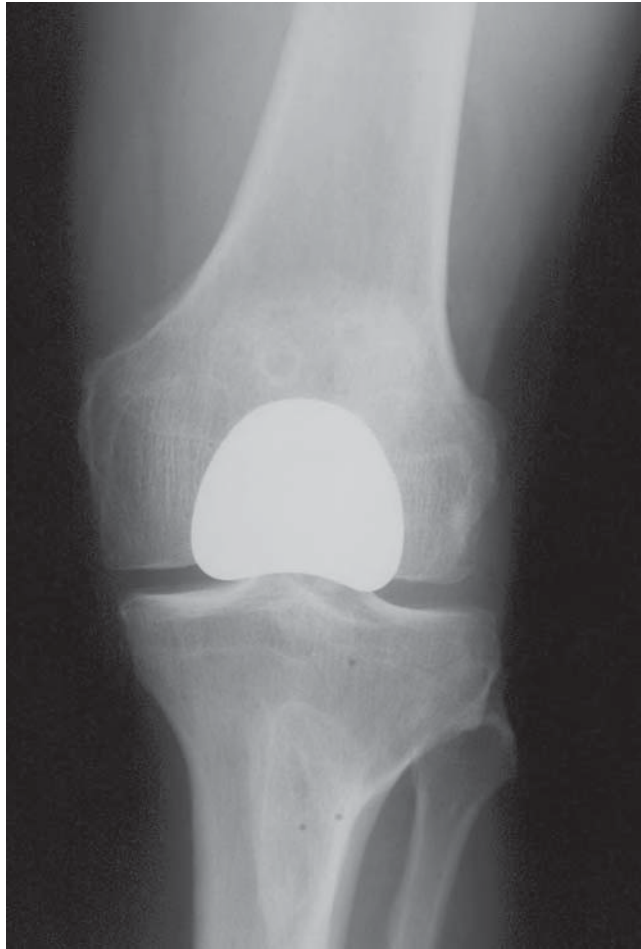

FIG. 15-A

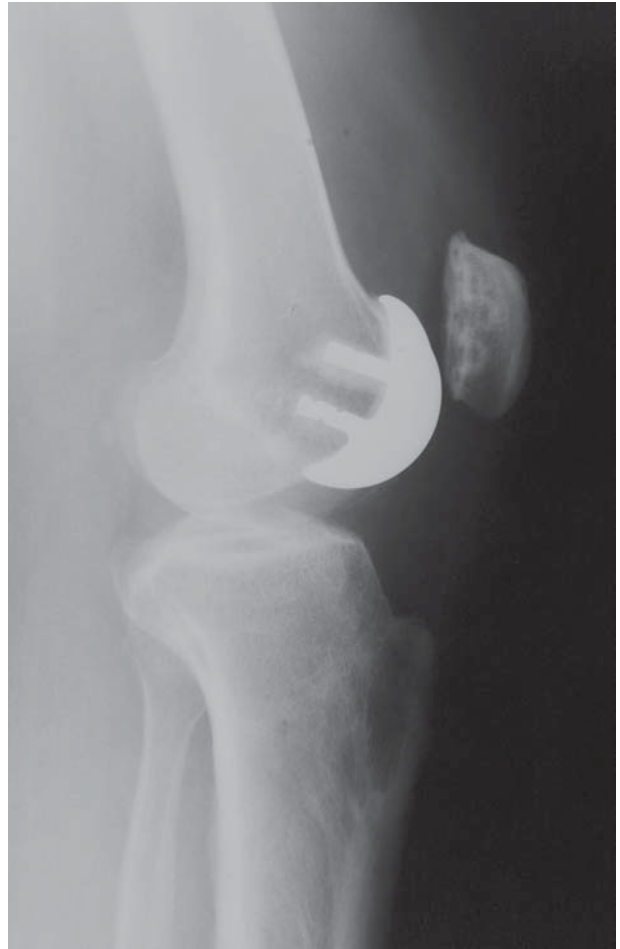

FIG. 15-B

Figs. 15-A, 15-B, and 15-C

Postoperative anteroposterior (Fig. 15-A), lateral (Fig. 15-B), and Merchant-view (Fig. 15-C) radiographs revealing proper placement of the component.

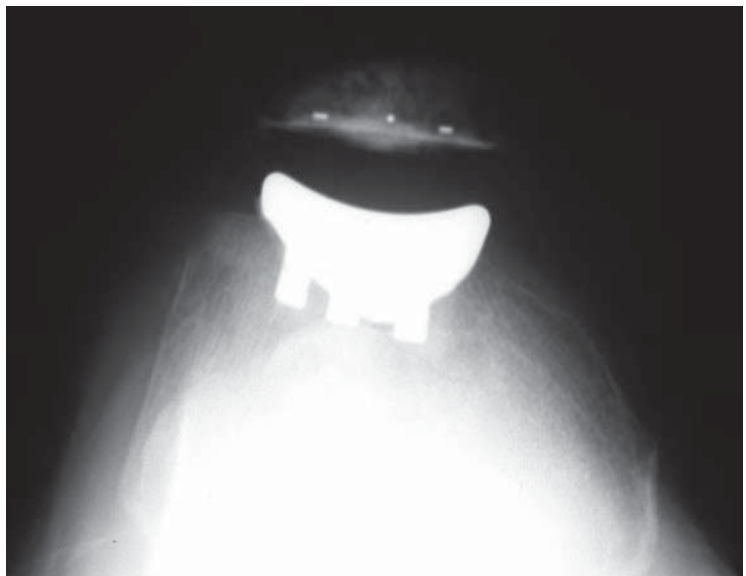


FIG. 15-C

oral medullary canal. The average hospital stay is generally between one and two days. Range-of-motion exercises are begun on the first postoperative

day, and a continuous-passive-motion machine is used for eight hours per day for two weeks to help maximize the range of motion. Patients are al-

lowed to walk immediately with full weight-bearing and the aid of a walker or crutches. No post-operative activity modifications are recommended.

CRITICAL CONCEPTS

INDICATIONS

(ADAPTED FROM LEADBETTER ET AL.²):

- Degenerative or posttraumatic osteoarthritis limited to the patellofemoral joint (Ahlback score^{3,4} of ≤ 1 point for arthritic severity at the medial and lateral tibiofemoral compartment)
- Severe symptoms affecting daily activity, referable to patellofemoral joint degeneration and unresponsive to six months of nonoperative treatment and failed prior conservative procedures
- Failure of a previous surgical procedure to unload the extensor
- Patellofemoral malalignment or dysplasia-induced degeneration with or without instability (Fig. 2)

CONTRAINDICATIONS

(ADAPTED FROM LEADBETTER ET AL.²):

- No attempt at nonoperative care or to rule out other sources of pain
- Ahlback score^{3,4} of > 1 point in the medial or lateral tibiofemoral compartment
- Inflammatory arthropathy
- Osteoarthritis and/or chondrosis of Kellgren-Lawrence⁵ grade 3 or less in the patellofemoral joint
- Uncorrected patellofemoral instability or malalignment
- Uncorrected tibiofemoral mechanical malalignment (valgus $> 8^\circ$ or varus $> 5^\circ$)
- Active infection
- Evidence of chronic regional pain syndrome
- Fixed loss of knee range of motion (surgical candidate must have -10° of extension to 110° of flexion at a minimum)
- Psychogenic pain

PITFALLS:

- Failure to correct patellar alignment and tracking intraoperatively
- Aggressive removal of femoral trochlear cartilage with a burr, causing unintentional removal of subchondral bone under the custom patellofemoral implant
- Under-resection of the patella, leading to overstuffing of the patellofemoral joint
- Non-adherence to the preoperative computed tomography-scanning protocol of the manufacturer, which must be followed to ensure that data are collected in the proper format
- Lack of communication with the manufacturer about any planned osteophyte removal prior to final implant design
- Overly aggressive interpretation of indications. In our experience, approximately 3% of our knee arthroplasty patients have the correct indications for an isolated patellofemoral replacement.

AUTHOR UPDATE:

We have made no substantive changes to the surgical technique since the publication of the original article⁶. We now use two 3-mm pins to stabilize the custom drill-guide prior to drilling the peg holes. The patients included in our original series continue to do well, with no additional operations or complications.

Domenick J. Sisto, MD
Los Angeles Orthopaedic Institute, 4955 Van Nuys
Boulevard, Suite 615, Sherman Oaks, CA 91403.
E-mail address: laortho1@yahoo.com

Vineet K. Sarin, PhD
Kinamed, Inc., 820 Flynn Road, Camarillo, CA
93012-8701

REFERENCES

1. Metcalf RW. Operative arthroscopy of the knee. Instr Course Lect. 1981;30:357-96.
2. Leadbetter WB, Seyler TM, Ragland PS, Mont MA. Indications, contraindications, and pitfalls of patellofemoral arthroplasty. J Bone Joint Surg Am. 2006;88 Suppl 4:122-37.
3. Ahlback S. Osteoarthritis of the knee. A radiographic investigation. Acta Radiol Diagn (Stockh). 1968;Suppl 277:7-72.
4. Mont MA, Haas S, Mullick T, Hungerford DS. Total knee arthroplasty for patellofemoral arthritis. J Bone Joint Surg Am. 2002;84:1977-81.
5. Kellgren JH, Lawrence JS. Radiological assessment of osteoarthrosis. Ann Rheum Dis. 1957;16:494-502.
6. Sisto DJ, Sarin VK. Custom patellofemoral arthroplasty of the knee. J Bone Joint Surg Am. 2006;88:1475-80.